

Perichondrium Graft: Harvesting and Indications in Nasal Surgery

Armando Bocchieri, MD, and Tito M. Marianetti, MD

Abstract: Irregularities in the nasal contour of patients who underwent multiple surgeries are frequently related also by skilled surgeons. The aim of this study was to describe the method of harvesting and the primary applications of erichondrium grafts in revision rhinoplasty to prevent postoperative irregularities.

Conchal grafts were used in the reconstruction of structures missing as a result of rhinoplasty. The perichondrium was removed from the cartilage during harvesting and fixed on the cartilaginous grafts to fill up empty spaces and make uniform the surface of the grafts. These techniques were used on 62 patients.

All of the patients treated showed aesthetic improvement with respect to the preoperative situation. Comparison with other cases in which the perichondrium graft was not used demonstrates its effectiveness in avoiding certain sequelae over time, especially as regards the presence of unattractive sharp edges often visible beneath the cutaneous covering after the use of structural grafts.

In conclusion, perichondrium grafting during secondary rhinoplasty is an easily performed technique that involves a small increase in operating time if combined with the harvesting of conchal material. Its application over the surface of cartilage grafts constitutes a stable covering over time that protects the definitive result from irregularities caused by the disappearance of postoperative edema and scar retraction.

Key Words: Revision rhinoplasty, perichondrium graft, reconstructive rhinoplasty, autologous graft

(*J Craniofac Surg* 2010;21: 40–44)

It is common practice in revision rhinoplasty to perform cartilaginous structural grafting using material taken from the nasal septum or the auricular and costal cartilage, in order of preference.¹ Septal cartilage is, however, often available in limited amounts as a result of previous operation, and material is therefore taken from the auricular concha.² At the same time, although very safe in taking root and infection, cartilage grafts can create problems of visibility beneath the cutaneous covering over time.³ This sequela, which can also manifest itself a long time after the operation, is unquestionably

more probable in cases where the skin is rather thin and the edges of the graft have not been rounded sufficiently. The close proximity and contact of different grafts can also lead in time to the perception of unattractive ridges in the nasal profile. The use of the perichondrium appropriately harvested from the auricular concha has already been suggested more than once as an excellent way of covering grafts so as to conceal the irregularities beneath. Its protective effect on the final result becomes evident a long time after, when the masking caused by the postoperative edema disappears and the cartilaginous grafts are exposed to the pressure of scar contraction of the surrounding tissues.

This article describes a method of preparing perichondrial material harvested from the auricular concha and presents a codified technique for grafting onto the nasal structures. Some guidelines are provided as regards the primary indications and the results of clinical experience. The advantages of the perichondrial graft in comparison with other autogenous or alloplastic grafts are reviewed.

PATIENTS AND METHODS

The study regards the use of perichondrium grafts on 62 patients (45 women and 17 men) submitted to revision rhinoplasty between February 2002 and April 2006. Thirty of the patients had previously undergone more than 1 (2–4) rhinoplasty. Although the primary indication for surgical treatment was iatrogenic aesthetic deformity, functional disorders were also present in approximately 30% of the cases. The latter were examined by means of basal rhinomanometry followed by decongestion in accordance with the method described by Constantian and Clardy.⁴ Preoperative aesthetic assessment of the patients was based on photographs showing 6 views: frontal, basal, left and right lateral, and three-quarter. The specific nasal deformities present were catalogued as regarding the upper third (bony pyramid), middle third (cartilaginous pyramid), and lower third (tip, ala, and columella), with at least 2 anatomic nasal sections simultaneously involved in 46 cases. They comprised a saddle deformity, osteotomy irregularities, scar adhesions, asymmetries, a narrow nasal vault, a pollybeak deformity, and the continuing presence of deviation in the upper and middle third and overprojection or underprojection of the nasal tip, deviation, asymmetry, alar collapse, columellar retraction, and bossae to varying degrees in the lower third. Perforation of the nasal septum was present in 3 cases. More than 1 structural graft was indicated in all the cases. Because the nasal septum was insufficient for this purpose, material was taken from one or both sides of the concha. Onlay grafts were used in the upper third to correct various degrees of saddleback deformity. Spreader grafts⁵ were used in the middle third to correct deficits of the internal nasal valve and continuing deviation of the dorsum. Alar batten grafts⁶ were used in the lower third to reconstruct the alar cartilages and the external nasal valve. Underprojection of the nasal tip required the use of shield grafts⁷ or onlay grafts,⁸ often combined with columellar struts.⁹ An open approach to the nasal pyramid with an inverted-V columellar incision was adopted in all cases.

From the Department of Maxillofacial Surgery, San Camillo Hospital, Rome, Italy.

Received May 20, 2009.

Accepted for publication May 25, 2009.

Address correspondence and reprint requests to Tito M. Marianetti, MD, San Camillo Hospital, V.le delle Province 55 int. 18, 00162 Rome, Italy; E-mail: titomatteo.marianetti@it

Copyright © 2010 by Mutaz B. Habal, MD

ISSN: 1049-2275

DOI: 10.1097/SCS.0b013e3181c362df

TECHNIQUE

The harvesting of conchal cartilage is carried out by means of a retroauricular approach so as to leave no visible scar. Infiltration of xylocaine with adrenaline (1:100,000) is carried out on both sides of the concha followed by a vertical median-posterior incision. The tissues above the concha are detached so as to avoid exposing the cartilage completely and leave the perichondrium attached to its posterior surface. Particular care must be taken in this phase to avoid lesions of the perichondrial covering. To this end, it proves advisable to subject the cutaneous strip to firm posterior traction and use the scalpel for detachment purposes.

The outline of the graft is then traced by inserting 4 or 5 straight needles into the anterior surface, taking care to leave the fold of the antihelix and the root of the helix intact.¹⁰ This makes it possible to cut the cartilage of the concha with no risk of impairing the morphology of the auricular pavilion. At this point, the anterior surface of the graft is subjected to subperichondrial detachment, freed completely, and removed. The cutaneous incision is sutured with 5.0 nylon. If this is carried out by another surgeon, preparation of the perichondrium graft can proceed at the same time.

Detachment of the perichondrium from the cartilage of the auricular concha constitutes an essential stage in this technique. The concha must be held firmly in a horizontal position with its posterior surface on top. This can be done either by securing it to a support with needles or by having an assistant hold it firmly in 2 cartilage forceps. As the perichondrium is very strongly attached to the cartilaginous surface, its detachment must be carefully executed with sharply pointed scissors, proceeding edgewise from one end to the other (Fig. 1). The use of an elevator has proved risky because the tissue is easily torn. Before completing the detachment, it is advisable to suture the outer side of the perichondrium with 1 stitch of 6.0 nylon so that it can be correctly positioned during the graft onto the nasal structures (Fig. 2). The strip of perichondrium should then be placed on gauze and kept moist through frequent irrigation with a saline solution.

The use of this graft is essentially indicated for the nasal dorsum and tip. It proves useful in the case of a saddle nose deformity in eliminating the gaps that inevitably form between the cartilaginous onlay graft and the surrounding structures. Insertion of the graft can be facilitated by further moistening and its positioning by a combination of external palpation and internal adjustment by means of forceps. It is not necessary to secure the graft in these cases because the rough surface of the perichondrium adheres to the

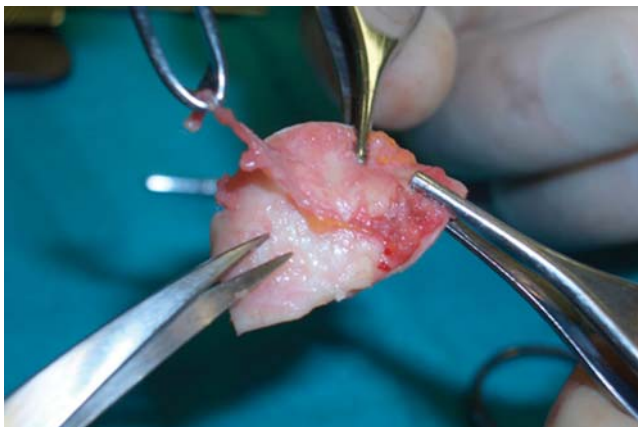


FIGURE 1. Removal of the perichondrium from the cartilage of the auricular concha.

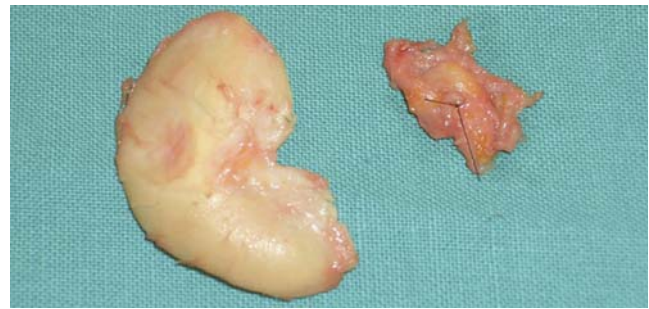

FIGURE 2. Left, Auricular concha. Right, Perichondrium with a suture of 6.0 nylon on its outer surface.

anatomic structures beneath it as soon as the watery component is dispersed. To this end, it can be useful to apply light pressure from the outside, combined in any case with careful taping of the nasal ridge at the end of the operation. The graft can also be used in a very similar way to deal with scar adhesions between the skin and the supporting structures beneath. In such situations, the 2 layers are separated and the graft is inserted between them to provide thickness, permit sliding, and prevent relapse.

Perichondrial tissue can be used in connection with the nasal tip to attenuate the unevenness between the shield or Peck grafts and the surrounding cartilages or other grafts and thus make the edges smoother (Figs. 3A–C). The depression between the tip and the supratip, commonly known as the supratip break, can also prove excessive during the operation and be attenuated through suitable positioning of the perichondrium graft in that area. In other cases, reconstruction of the tip involves suturing portions of the medial to lateral crura or conchal grafts and inevitably leads to the formation of ridges between the cartilages. Here too, the perichondrium graft can serve to restore apparent external continuity to all the structures (Fig. 4). In all of these cases, the graft must first be secured to the surrounding structures with fine sutures of 6.0 nylon and then cut and reshaped according to requirements with finely pointed scissors.

In the case of perforation of the nasal septum, after using a suitable technique to detach the mucosa and suture the perforation,¹¹ a perichondrium graft can be placed between the 2 flaps so as to provide a further barrier against relapse. If the mucosa is insufficient for complete closure of the perforation, a small portion of the graft can be left uncovered on 1 of the 2 sides. Great importance attaches in any case to securing it in the right position with a number of long-term absorbable mattress sutures.

RESULTS

All of the patients underwent revision rhinoplasty using a perichondrium graft. Improvement of the preoperative nasal deformity was obtained in all the cases. Follow-up ranged from 30 to 60 months (median, 42 mo). There were no instances of infection, movement, or substantial absorption of the grafts. Satisfactory results were achieved in all the cases as regards reconstruction and aesthetic appearance together with an improvement in nasal functionality wherever an obstructive syndrome was present. Positive aesthetic judgements were expressed not only by the operating team but also by the surgeons involved in the control tests, the family physicians, and the patients themselves. Only 1 patient, affected by saddle nose deformity, required further revision surgery, not because of the perichondrium graft but to raise the height of the profile. The correction was achieved by supplementing the grafts present with another onlay graft of cartilage from the contralateral concha.

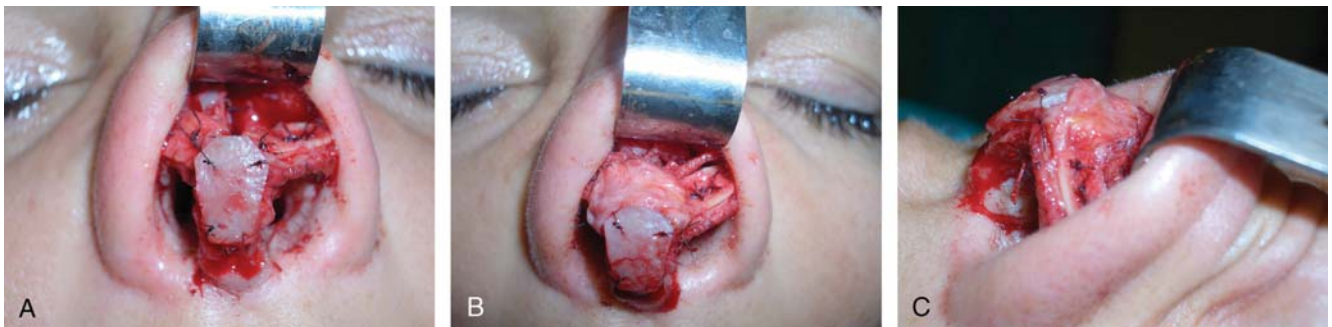

FIGURE 3. A, Reconstruction of the nasal tip with lateral crural and shield grafts (Sheen type) harvested from the cartilage of the auricular concha. B, Graft of the perichondrium stretched over and secured to cartilaginous grafts to make the contours smooth and disguise tip grafts. C, Lateral view of the same graft.

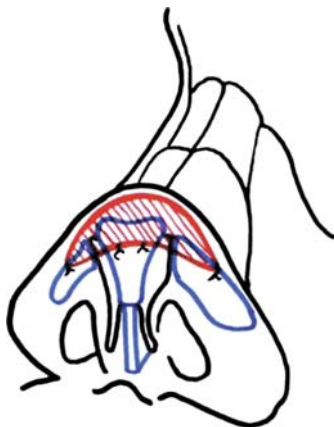


FIGURE 4. Schematic illustration of the perichondrium graft positioning and fixation. Presence of numerous grafts inevitably leads to sharp ridges and irregularities in the cartilaginous contour that can be eliminated by means of the perichondrium graft.

In the cases involving an obstructive syndrome, the comparison of preoperative and postoperative rhinomanometric data showed a decrease in nasal resistance and an improvement in nasal functionality. As regards the 3 operations for perforation of the septum, a complete closure was obtained in 2 cases (diameter, 2 and 3 cm) and an almost complete closure was obtained in the other (diameter, 3 cm).

Attention should be drawn to the presence in 3 cases of substantial swelling of the tip for more than 3 months. These patients also returned to the mean range of values after 3 injections of triamcinolone administered at intervals of approximately 3 weeks.

The postoperative photographs of 2 patients subjected to multiple cartilaginous grafts of the tip with a covering perichondrial graft show a soft nasal contour with no underlying irregularities (Figs. 5 and 6).

DISCUSSION

Even experienced surgeons have complained of the appearance of irregularities in the nasal dorsum and the tip after revision rhinoplasty. The use of multiple grafts with sharp edges and the presence of thin skin and scar tissue are risk factors for this problem. It has therefore been suggested that various materials should be used in high-risk cases so as to prevent this unwelcome sequela. Those most frequently used and reported in the literature are crushed cartilage,³ temporal fascia,¹² acellular dermis,¹³ and perichondrium.

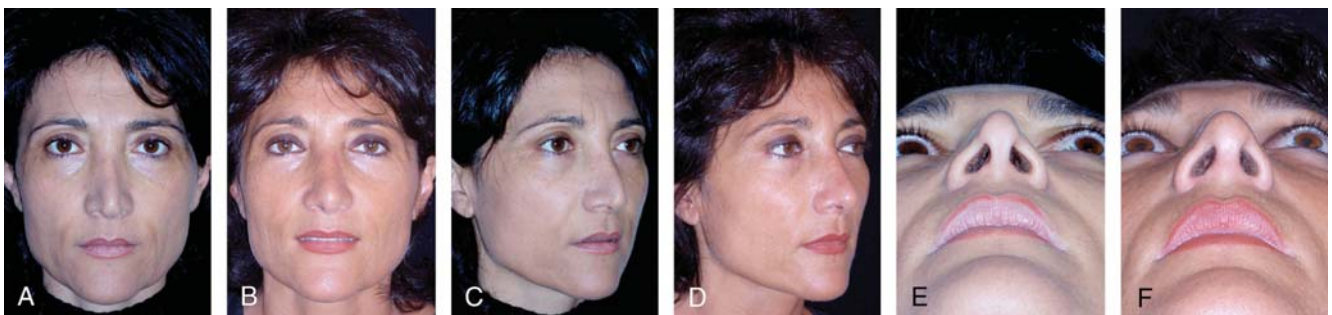

FIGURE 5. Patient submitted to 2 previous rhinoplasties with absence of both lateral crura, underprojection of the nasal tip, and scar adhesion between the skin and the nasal bone on the right. Reconstruction was performed by means of 2 lateral crural grafts and 1 shield graft of the auricular concha with a covering graft of the perichondrium. Another graft of the perichondrium was positioned between the skin and the bone in the right lateral wall. A, C, and E, Preoperative views. B, D, and F, Postoperative views.

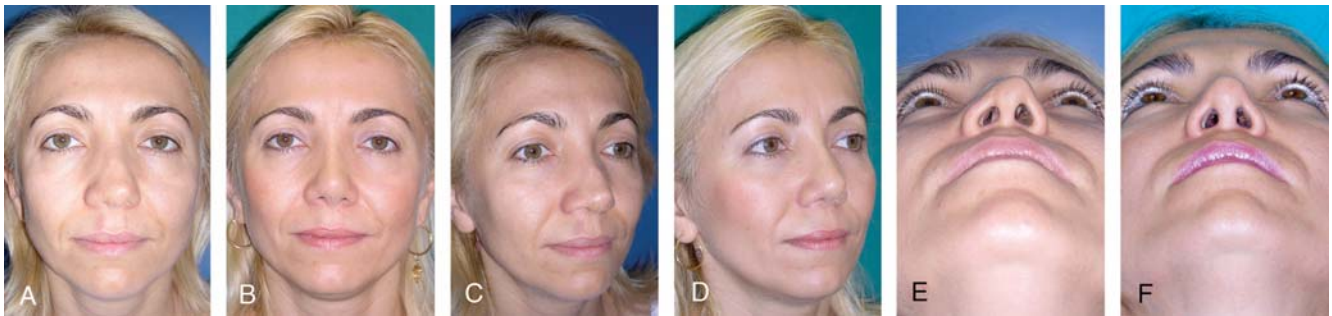

FIGURE 6. Patient subjected to 2 previous rhinoplasties with persistent deviation of the dorsal septum and underprojection and asymmetry of the nasal tip. Revision was performed by means of 2 spreader grafts, a right lateral crural graft, and an umbrella graft of the Peck type, all harvested from the auricular concha. A perichondrium graft was secured on top of the cartilaginous grafts of the nasal tip. A, C, and E, Preoperative views. B, D, and F, Postoperative views.

Whichever material is used, it must be positioned between the skin and the osteocartilaginous nasal supporting structures so as to cover and disguise any underlying sharp edges and asymmetries with its thickness. It can also perform associated functions of filling up small structural gaps and retouching for the purposes of reconstruction.

Although easy to shape, crushed cartilage possesses limited flexibility, tends to fragment, and can only be obtained from the septum, which is often insufficient or absent in cases of repeated surgical intervention. The temporal fascia proves very suitable for wrapping the structures below, but its use entails further harvesting and leaves another surgical scar, albeit one that is not visible. An acellular dermis is soft and natural despite being an allogeneic material but is also expensive and absorbable to a not-always-predictable degree. The perichondrium can easily be harvested from the concha with no need of additional surgical approaches, and the use of auricular cartilage is, in any case, very frequent in secondary rhinoplasties. Its thinness and malleability make it particularly suitable for covering every part of the cartilaginous grafts, and it is easy to fold into various layers if greater thickness is required in filling certain areas.

Numerous experimental studies have been carried out on rabbits to ascertain the potential of the perichondrium in cartilaginous cellular regeneration.¹⁴⁻¹⁶ Some more recent studies seem to have demonstrated the development of new cartilage subsequent to vascularized perichondrial grafts.¹⁷ The perichondrium has been used solely for reconstructive purposes in nasal surgery, and there are descriptions of operations to repair defects of the lower third with perichondrial cutaneous grafts or to close perforations of the nasal septum with perichondrial grafts adhering to the tragal cartilage.^{18,19} Although examination of the literature reveals no specific papers on the use of the perichondrium graft in rhinoplasty or descriptions of case studies, various references to its usage are made in a number of articles. There is a description of the use of this type of graft in the correction of bossae to smooth out the cartilaginous contour if the sharp edges of the cartilage remain apparent.²⁰ Attention has recently been drawn to its effectiveness in revision rhinoplasties to prevent the graft's showing after long-term follow-up and to ensure a smooth contour in cases involving a combination of shield and lateral crural grafts.^{21,22}

From a histological point of view, it has been recently demonstrated that the grafted perichondrium does not cause encapsulation or reactions triggered by an extraneous body. Over time, the graft does not show resorption and retains its histologic individuality.²³

Clinical experience has confirmed that the perichondrium graft seems particularly suitable for covering the cartilaginous grafts beneath so as to conceal their presence and provide a completely natural appearance over time. Even in cases where reconstruction

involves suturing cartilaginous structures together, the use of the perichondrium to cover the edges in contact creates anatomic continuity and provides protection against subsequent modification. In this connection, it can be suggested that the structures covered by the perichondrium are also strengthened by it and better able to resist the forces of scar contraction working to displace them.

The only negative aspect registered with this technique is the greater extent of swelling in the postoperative period, which in any case, disappears in a few months and should thus cause no concern. It is, however, advisable to warn patients of this fact before the operation and explain that it is a small price to pay for a better definitive result.

CONCLUSIONS

The technique combining a perichondrium graft with a graft of auricular concha is easy to perform and involves no additional harvesting sites or scars. The operating time added for removing and preparing the material can be minimal if this takes place while another surgeon performs the retroauricular cutaneous suture.

The technique is particularly useful in revision rhinoplasties involving a number of cartilaginous grafts that can become visible over time in the presence of thin skin and lead to irregularity of the nasal contour. It is also indicated in cases that involve the suturing of sections of cartilaginous structures, which can be displaced in time through scar contraction and show sharp ridges beneath the cutaneous covering. A further possibility is insertion of the perichondrium graft between the 2 mucosal flaps in operations to repair perforations of the nasal septum.

In all these cases, the perichondrium graft is easy to shape in accordance with requirements and secure to the surrounding structures with sutures. Clinical experience has shown no adverse effects of infection, absorption, or rejection of the graft. The only negative aspect is swelling to a greater extent than usual, which can be particularly marked at the tip but disappears slowly over time in any case.

The perichondrium graft has proved useful in optimizing the long-term results of revision rhinoplasty by preventing impairment and blemishes of the nasal contour.

REFERENCES

1. Quatela VC, Jacono AA. Structural grafting in rhinoplasty. *Facial Plast Surg* 2002;18:223-232
2. Becker DG, Becker SS, Saad AA. Auricular cartilage in revision rhinoplasty. *Facial Plast Surg* 2003;19:41-51
3. Sheen JH. Tip graft: a 20-year retrospective. *Plast Reconstr Surg* 1993;91:48-63
4. Costantian MB, Clardy RB. The relative importance of septal and nasal

- valvular surgery in correcting airway obstruction in primary and secondary rhinoplasty. *Plast Reconstr Surg* 1996;98:38–53
5. Sheen JH. Spreader graft: a method of reconstructing the roof of the middle nasal vault following rhinoplasty. *Plast Reconstr Surg* 1984;73:230–237
 6. Toriumi DM, Josen J, Weinberger M, et al. Use of alar batten graft for correction of nasal collapse. *Arch Otolaryngol Head Neck Surg* 1997;123:802–808
 7. Sheen JH. Achieving more nasal tip projection by the use of a small autogenous vomer or septal cartilage graft. *Plast Reconstr Surg* 1975;56:35–40
 8. Peck GC. The onlay graft for nasal tip projection. *Plast Reconstr Surg* 1983;71:27–37
 9. Foman S, Goldman IB, Neivert H, et al. Management of deformities of the lower cartilaginous vault. *Arch Otolaryngol* 1951;54:467–472
 10. Bocchieri A, Marano A. The conchal cartilage graft in nasal reconstruction. *J Plast Reconstr Aesthet Surg* 2007;60:188–194
 11. Kridel RWH. The open approach for repair of septal perforations. In: Daniel RK, ed. *Aesthetic Plastic Surgery: Rhinoplasty*. Boston: Little Brown & Company, 1993;555–566
 12. Miller TA. Temporalis fascia grafts for facial and nasal contour augmentation. *Plast Reconstr Surg* 1988;81:524–532
 13. Gryskiewicz JM, Rohrich RJ, Reagan BJ. The use of Alloderm for correction of nasal contour deformities. *Plast Reconstr Surg* 2001;107:561–570
 14. Skoog T, Ohlsèn L, Sohn SA. Perichondrial potential for cartilaginous regeneration. *Scand J Plast Reconstr Surg* 1972;6:123–125
 15. Ohlsèn L. Cartilage formation from free perichondrial grafts: an experimental study in rabbits. *Br J Plast Surg* 1976;29:262–267
 16. Ohlsèn L, Widenfalk B. The early development of articular cartilage after perichondral grafting. *Scand J Plast Reconstr Surg* 1983;17:163–177
 17. Hosokawa K, Hata Y, Yano K et al. Histological study of the development of cartilage after perichondral vascularized grafting. *Ann Plast Surg* 1987;19:515–518
 18. Gloster HM, Brodland DG. The use of perichondrial cutaneous grafts to repair defects of the lower third of the nose. *Br J Dermatol* 1997;136:43–46
 19. Eviatar A, Myssiorek D. Repair of nasal perforation with tragal cartilage and perichondrium grafts. *Otolaryngol Head Neck Surg* 1989;100:300–302
 20. Kamer FM. The nasal bossa: a complication of rhinoplasty. *Laryngoscope* 1986;96:303–307
 21. Vuyk HD, Watts SJ, Vindayak B. Revision rhinoplasty: review of deformities, aetiology and treatment strategies. *Clin Otolaryngol* 2000;25:476–481
 22. Toriumi DM. New concepts in nasal tip contouring. *Arch Facial Plast Surg* 2006;8:156–185
 23. Bocchieri A. The perichondrium graft in revision rhinoplasty. *Plast Reconstr Surg* 2008;122:216e–217e