

The Lateral Crural Stairstep Technique

A Modification of the Kridel Lateral Crural Overlay Technique

Armando Bocchieri, MD; Giuseppe Raimondi, MD

The Kridel lateral crural overlay technique has proved capable of resolving overprojection with severe ptosis of the tip and can be used along with a medial crural overlay to reduce marked overprojection of the tip with no significant rotation. In the technique described herein, the section of the lateral crus involved in the lateral crural overlay is step-shaped rather than vertical and the cartilage is completely detached from the skin beneath as far as the domus. The anterior segment is moved downward and is overlapped with the posterior segment on both sides to resolve “parenthesis deformities” of the nasal tip that are caused by malposition of the lateral crura. This procedure can also be combined when necessary with both posterior and anterior sliding of the lateral crus to correct most deformities of the nasal tip. Within the framework of surgery on the nasal tip, attention has focused primarily on techniques that were designed to modify the projection and rotation of the nasal tip. It is only recently that a new parameter with important aesthetic and functional implications has emerged, namely cephalocaudal positioning in the space of the lateral crura.¹

Cephalic malpositioning of the lateral crura gives rise to a parenthesis deformity of the nasal tip that can manifest alone or along with defects of projection and rotation to varying degrees.² The caudal margin of the lateral crura can also be anatomically oriented in a position markedly below the cephalic margin, which results in a lack of support for the alar lobule and the alar margin.³ In some cases, it is precisely the dome suturing that causes displacement of the caudal margin of the lateral crura beneath the cephalic margin. In others, the weakening of the domus that is sometimes caused by surgery makes it unable to resist the scar contraction that pushes the lateral crura upward. In all these situations, from an aesthetic viewpoint, there is a clear separation between the tip lobule and the alar lobule, with a pinched and unnatural appearance of the nasal contour. In functional terms, there can be respiratory difficulties of varying degree ow-

ing to insufficiency of the external nasal valve caused by lack of structural support for the alar margin.

While careful preoperative clinical analysis can identify most situations of congenital or acquired malpositioning of the lateral crura, the precise scale of the pathologic condition is revealed only by direct intraoperative observation using open access. The corrective surgical technique must seek to reposition the lateral crura, bearing in mind that the nasal tip is particularly satisfactory from an aesthetic viewpoint when its contour is horizontally oriented in the frontal view. A position in which the 2 cephalic margins of the lateral crura form an angle of approximately 90° is considered ideal in this respect. Another surgical objective is to place the caudal margin of the lateral crus at the same level as the cephalic margin. When necessary, the repositioning of the lateral crura must obviously form part of a broader surgical plan that also involves correction of the projection and rotation of the tip.

Author Affiliations: Department of Maxillofacial Surgery, S. Camillo Hospital, Rome, Italy (Dr Bocchieri); and Department of Otorhinolaryngology, United Hospitals, Livorno, Italy (Dr Raimondi).

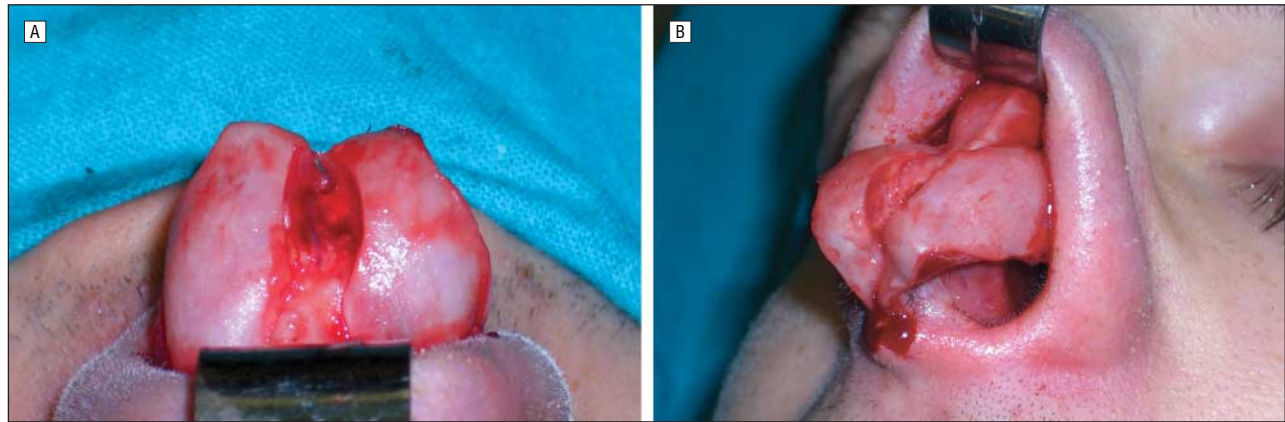


Figure 1. Intraoperative view of malpositioning of lateral crura. A, Cephalically positioned lateral crura. B, Caudal margin of lateral crura placed below cephalic margin.

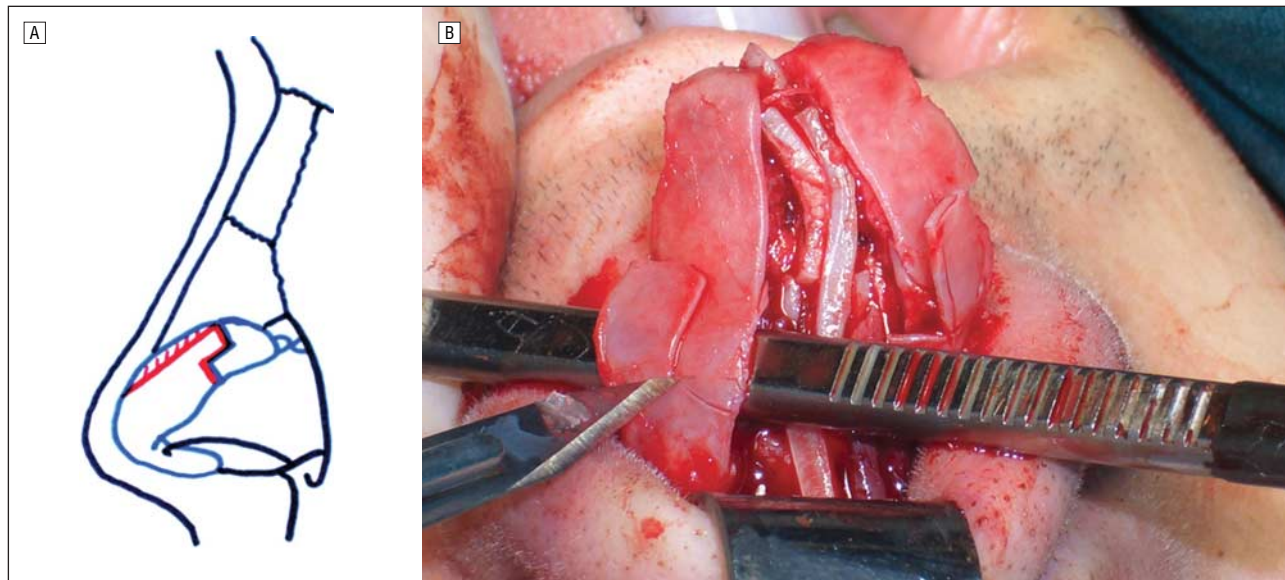


Figure 2. Lateral crural stairstep technique. A, Schematic drawing of stairstep incision. B, Intraoperative view of incision.

TECHNIQUE

Open access is performed to expose the alar cartilages and nasal dorsum. To this end, an inverted V-shaped columellar incision is made along with 2 marginal incisions of the nasal vestibule. The marginal incisions are made in a more caudal position with respect to the lower margin of the lateral crura in order to accommodate the repositioned cartilages. Careful detachment and isolation of the tip reveal the cephalic malposition of the lateral crura and the abnormal relationship between their cephalic and caudal margins, with the latter lying beneath the former (**Figure 1**).

Reshaping of the nasal tip generally requires the conservative excision of a strip of cartilage from the cephalic portion of the lateral crura, leaving at least 6 to 7 mm of residual cartilage. This step is followed immediately by a stairstep incision in the posterior third of the posterior portion of the lateral crura, leaving the skin of the nasal vestibule beneath intact (**Figure 2**) and yielding 2 segments of lateral crural cartilage on both sides: 1 anterior segment, which is secured to the

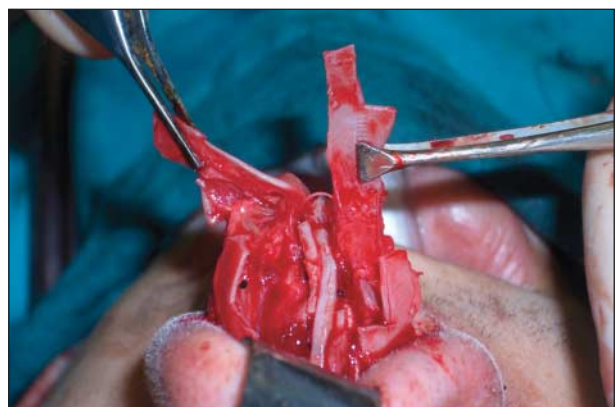


Figure 3. Detachment of anterior segments of lateral crura from skin of nasal vestibule beneath as far as the domus.

domus, and 1 posterior segment, which is secured to the pyriform aperture. The cartilage is completely detached from the skin beneath as far as the domus, starting from the incision and working outward from the rear, in order to completely free an anterior flap of the

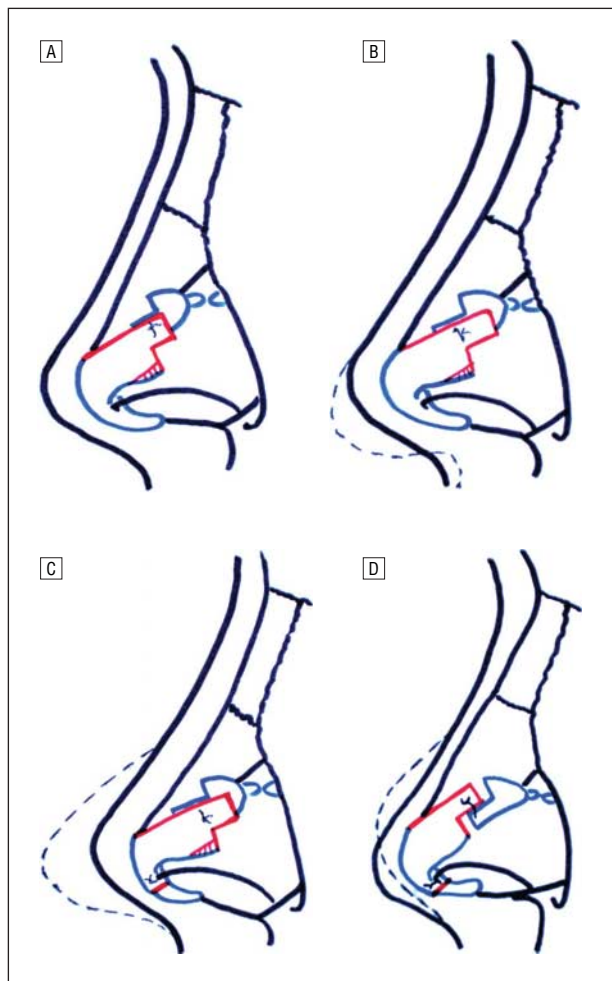


Figure 4. Surgical options of the lateral crural stairstep technique. A, Correction of a pure parenthesis deformity. B, Correction of malposition of lateral crura combined with overprojection and ptosis of tip. C, Correction of malposition of lateral crura combined with marked overprojection of tip. D, Correction of overprojection and overrotation of tip with no malposition of lateral crura.

lateral crura (**Figure 3**). The posterior segment of the lateral crura must also be detached for a few millimeters working backward.

Then, the spatial repositioning of the lateral crura can be undertaken. There are 5 surgical options, depending on the case in question. First, when a parenthesis deformity with no other impairments of the nasal tip is involved, the lateral crura are moved downward and the upper step is secured on top of the lower step (**Figure 4A**). Second, when there is the lateral crura with overprojection and ptosis of the tip, the downward movement of the anterior flap is combined with overlapping and sliding backward on the posterior flap to attain the desired degree of rotation and projection (Figure 4B). Third, when the malposition of the lateral crura is accompanied by marked overprojection of the nasal tip, it is also possible to use the medial crural overlay technique,⁴ in which both the medial crura are sectioned and secured in an overlapping position (Figure 4C). Fourth, even when there is no malposition but there is overprojection of the tip along with evident overrotation, combining a medial crural overlay with the lateral crural

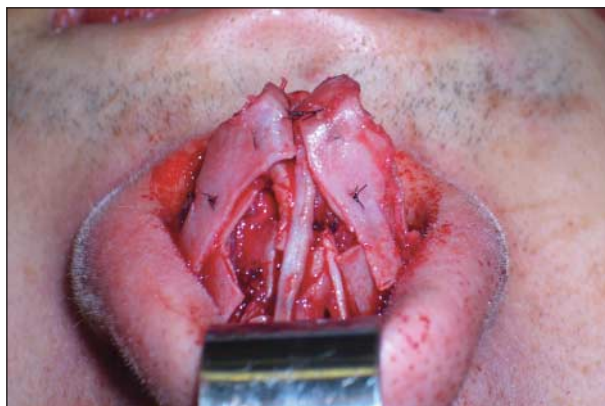


Figure 5. Suturing of cartilage segments with 6.0 nylon.

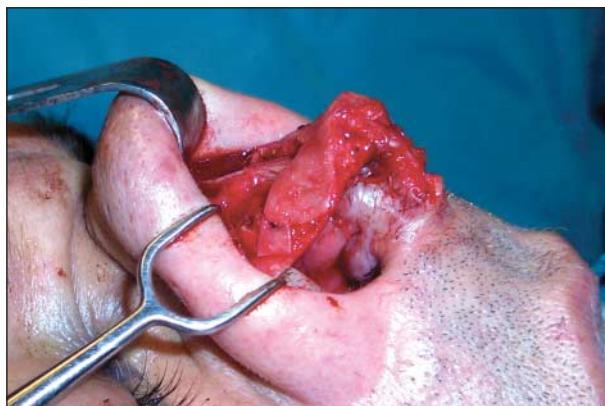

Figure 6. The caudal margin of the domus is slightly higher than the cephalic margin.

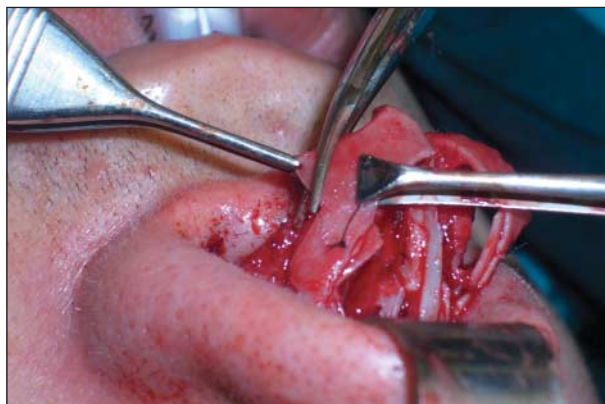


Figure 7. Removal of protruding cartilage from the lower margin of lateral crura.

stairstep technique can prove to be very useful. Reduction of the projection and rotation of the tip can be enhanced by shifting the anterior flap forward with no overlapping and by simply suturing the margins of the 2 segments (Figure 4D). In all of the above-mentioned surgical options, the cartilaginous segments are secured to one another by means of sutures with 6.0 nylon, while the skin beneath is secured to the lateral crura by means of mattress sutures of 5.0 polyglactin 910 (Vicryl) with the knots on top (**Figure 5**).

The caudal margin of the domus should also be slightly higher than the cephalic margin. This ideal po-

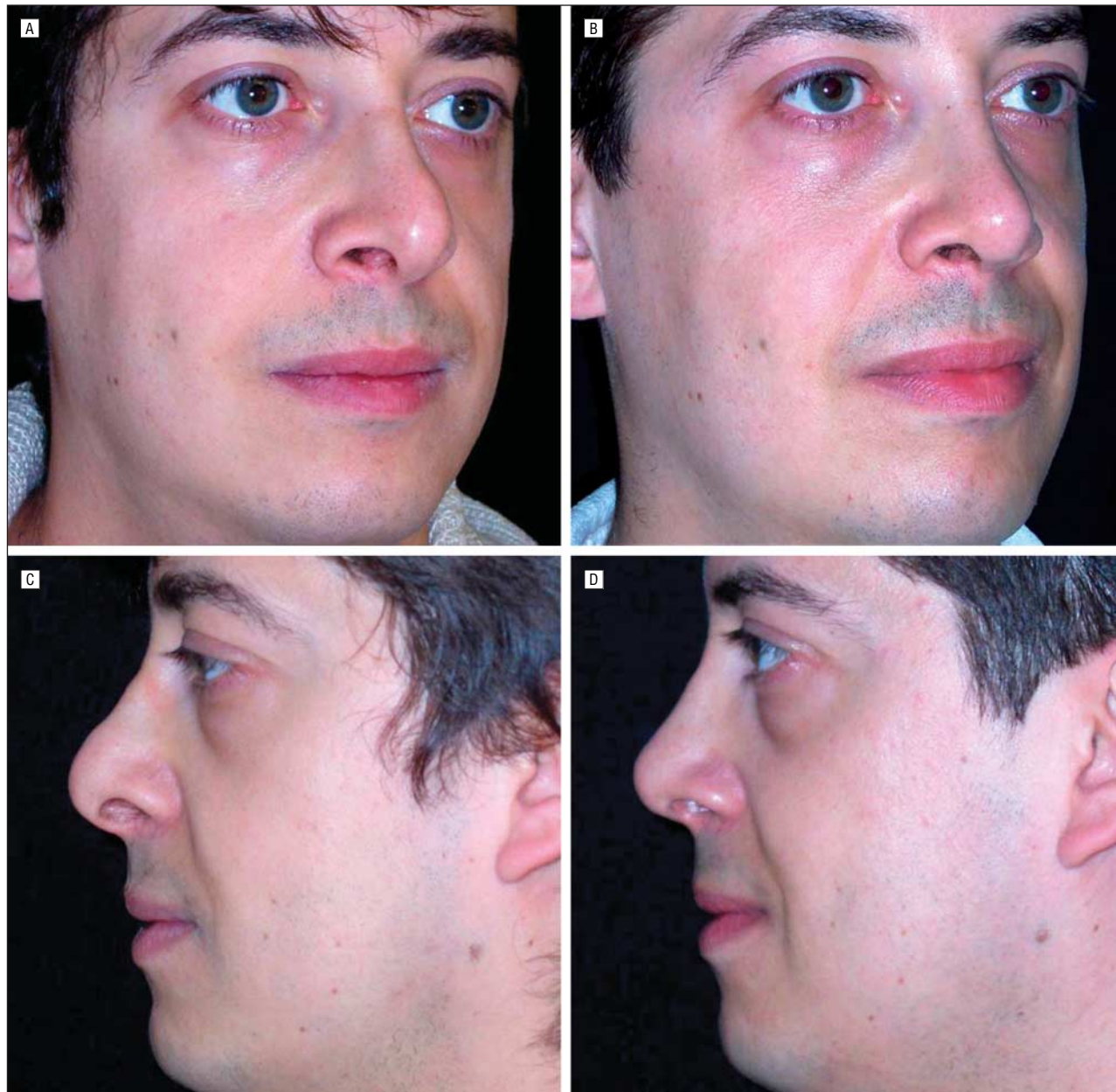


Figure 8. Patient who underwent a previous rhinoplasty with nasal wings pinched. Correction was performed via the lateral crural stairstep technique without removal of the lower margin of the lateral crura (fifth surgical option of the technique)). A and C, Preoperative views; B and D, postoperative views after 13 months.

sition of the alar cartilages can be obtained by downward and outward rotation of the lateral crura with a cephalic-posterior interdomal suture as a fixed point of reference (**Figure 6**). After suturing, scissors can be used to remove any surplus material, protrusions, or asymmetries in the lower margin of the lateral crura (**Figure 7**). On the contrary, downward protrusion of the lateral crura can prove useful in revision rhinoplasty to eliminate pinching of the alar margin. This situation constitutes the fifth surgical option (**Figure 8**). The medial crura are normally strengthened by means of a columellar strut taken from the nasal septum or by using the tongue-in-groove technique.⁵ In the latter case, the caudal septum is inserted and secured between the medial crura, which has the

further effect of correcting droopy nose with excessive columellar show. A transdomal suture often proves useful at the end of the procedure to improve nasal tip definition. The marginal incisions are then sutured with 5.0 polyglactin 910 and the columellar incision with 6.0 nylon. The procedure ends with the insertion of an anterior nasal tampon, which is removed after 24 to 48 hours, and the application of an external splint.

The lateral crural stairstep technique can be carried out alone or combined with other complex techniques. In any case, the reshaping of the tip should be left until last to avoid the risk of disrupting the delicate relationship between the juxtaposed cartilage segments with other maneuvers. The preoperative and postoperative photographs of a typical case illustrate the correction of a pa-

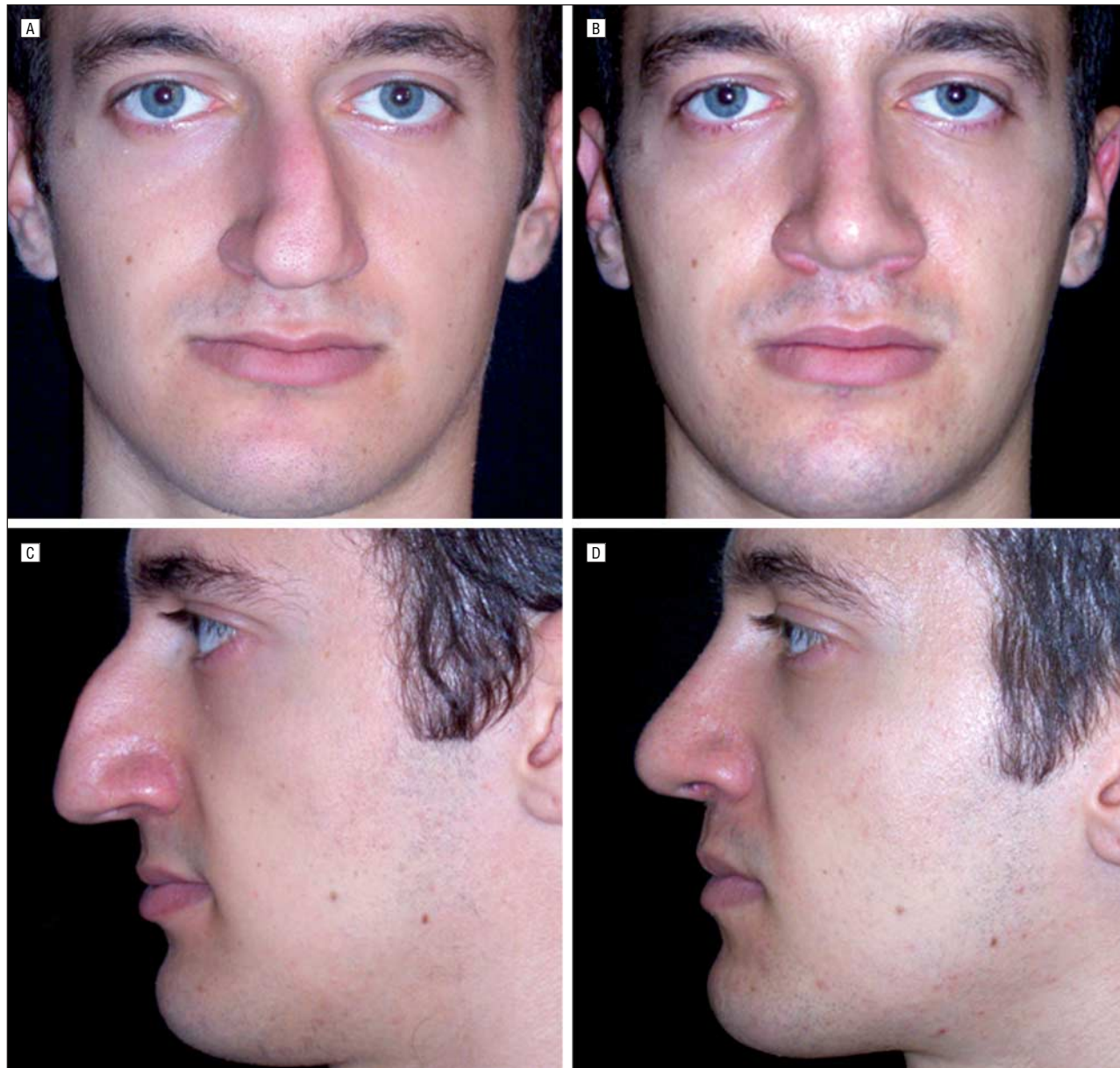

Figure 9. Patient who presented with dorsal hump, crooked nose, and cephalic malposition of lateral crura with overprojection and ptosis of the tip. Correction was performed via hump excision, septal crossbar graft technique, and lateral crural stairstep technique. Anterior segments of lateral crura were moved down and back to overlap with posterior segments. A and C, Preoperative views; B and D, postoperative views after 1 year.

renthesis deformity of the tip along with hump excision and the correction of crooked nose by means of the septal crossbar graft technique (**Figure 9**).^{6,7} The intraoperative photographs of the case in question are those presented previously in the description of the surgical procedure. To demonstrate the versatility of the lateral crural stairstep technique, each of the other situations in which it can be used is illustrated with long-term follow-up photographs taken 1 year after surgery (**Figures 10, 11, and 12**).

RESULTS

Between January 2005 and March 2006, a total of 22 patients (14 men and 8 women) underwent rhinoplasty via the lateral crural stairstep technique. The patients'

ages ranged from 22 to 60 years (average age, 37 years). While the parenthesis deformity alone was present in 5 cases, it was also found along with other deformities of the nasal tip, being combined with overprojection and ptosis in 7 cases and marked overprojection in 4 cases. Pinching of the nasal wings was present in 3 cases as a result of previous rhinoplasty, and 3 patients had overprojection along with overrotation as a result of iatrogenous factors in 2 cases. Other deformities regarding both the middle nasal vault and the upper third were also present in 15 cases: osteocartilaginous hump in 10 cases, deviation of the nasal pyramid in 5 cases, and both in 7 cases. Other techniques were also used to correct the deformities in these cases, but there were no negative effects due to the use of the lateral crural stairstep technique. The only difficulty in the execution

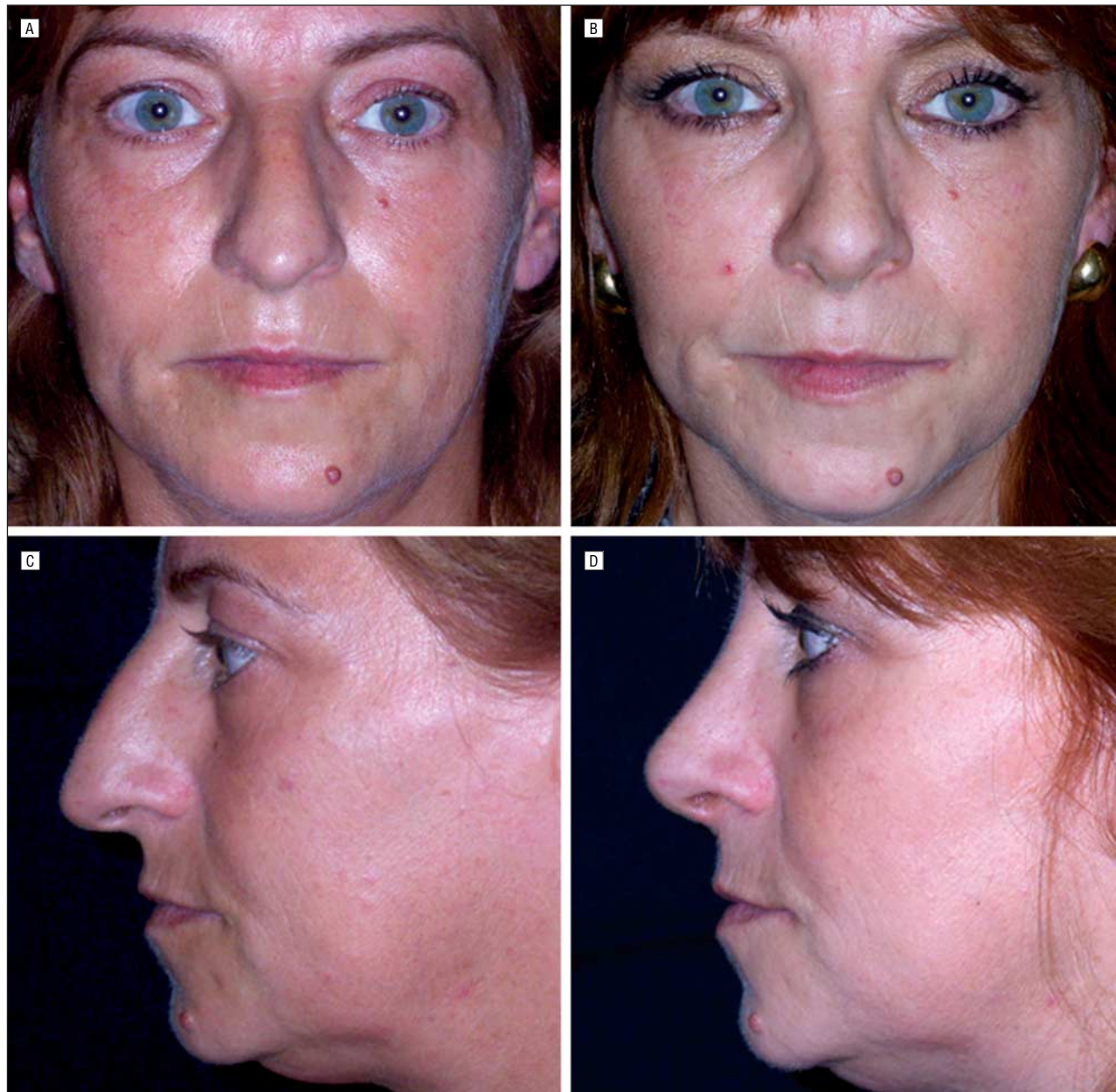

Figure 10. Patient who presented with malposition of the lateral crura with overprojection and ptosis of the tip (correction performed with surgical option in Figure 4B). A and C, Preoperative views; B and D, postoperative views.

of this technique arose during detachment of the lateral crura, when laceration of the underlying cutaneous lining occurred more than once. There were no postoperative complications, however, and the risk of laceration could be reduced by administering an abundant dose of local anesthetic plus a vasoconstrictor shortly before detachment. The follow-up period ranged from 12 to 14 months. A substantial improvement in the shape and spatial orientation of the lateral crura, as well as balanced values for the parameters of rotation and projection, was observed in all cases. These positive results were noted not only by the surgical team but also by the other physicians involved in the subsequent checks and above all by the patients themselves. Surgical revision was required in only 1 case because of a supratip deformity of cicatricial origin and was not associated in any

way with the use of the lateral crural stairstep technique.

COMMENT

The Anderson tripod theory represents a milestone in the history of surgery on the nasal tip.^{8,9} It describes the joined medial crura as 1 leg and the lateral crura as the other 2 legs. The variations in the length of the 3 elements produce modifications in the rotation and projection of the tip, leading to many of the deformities presented by patients. In this theoretical model, however, the lateral crura are represented as straight segments, while they are actually flat anatomical structures with variable 3-dimensional orientation in space. The tripod concept therefore fails to cover all the situations involving malposition

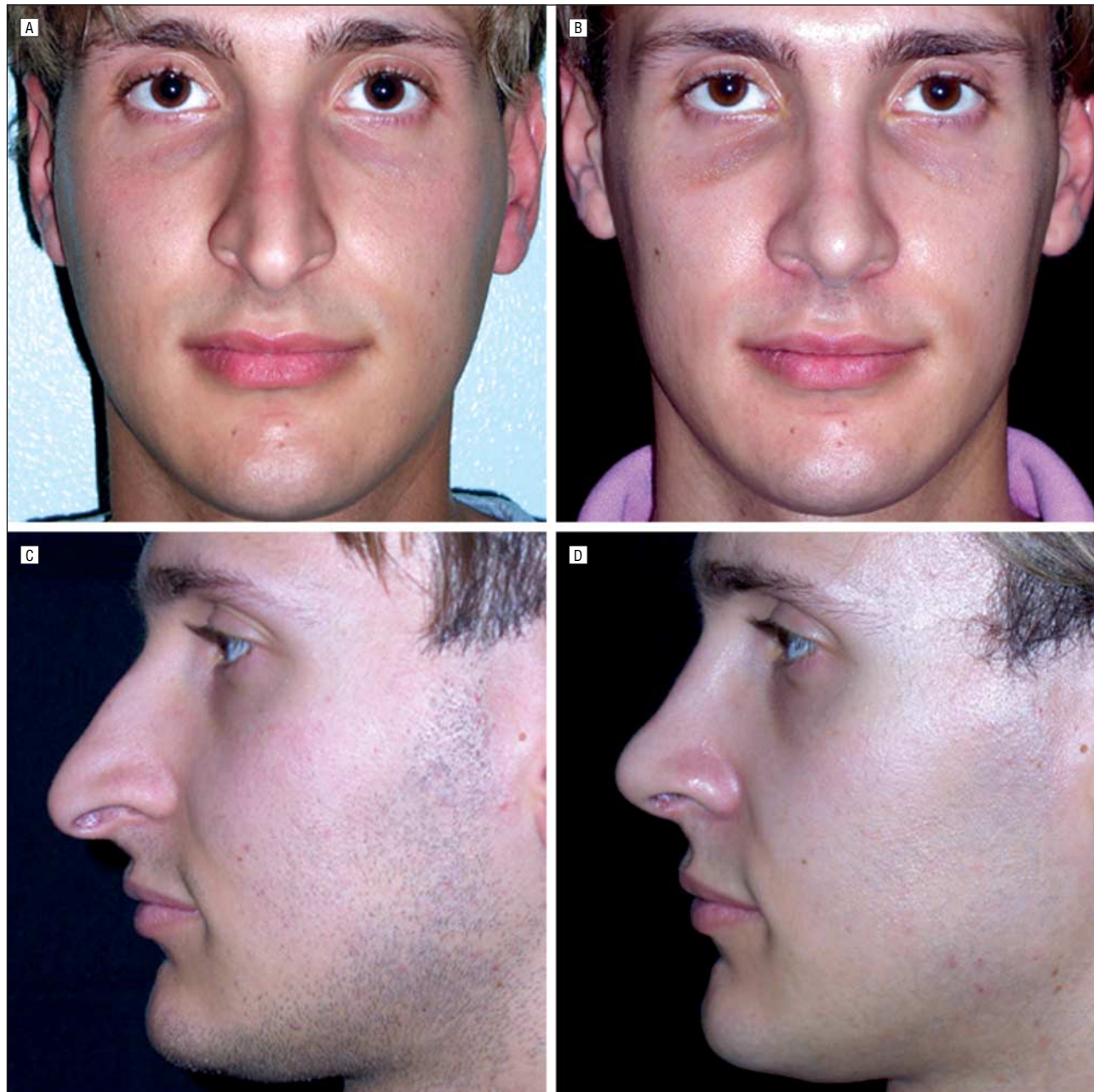

Figure 11. Patient who presented with malposition of the lateral crura with overprojection of the tip (correction performed with surgical option in Figure 4C). A and C, Preoperative views; B and D, postoperative views.

of the lateral crura with or without impairment of the projection and rotation of the nasal tip. At the same time, cephalic positioning of the lateral crura and vertical orientation of their anatomical plane also lead to major aesthetic and functional problems in the presence of correct tip projection and rotation.

Either alone or combined with medial crural overlay, the lateral crural overlay technique proposed by Kridel and Konior¹⁰ in 1991 offers an excellent way of resolving all the pathologic variants regarding tip projection and rotation with no weakening of the anatomical structures. The sliding, overlapping, and suturing of the segments make it possible to adjust these 2 important parameters, while preserving the continuity of the cartilaginous

arch. The use of a step-shaped rather than vertical section of the lateral crura makes it also possible to adopt the technique in cases involving the malposition of alar cartilages in that the anterior segment of the lateral crura can be detached and sutured in a lower position while kept firmly secured to the posterior segment. Other surgical procedures used for the same purpose of correcting parenthesis deformity involve detachment of the lateral crus as a whole, removal from the pyriform aperture, and repositioning at a lower level. Given the absence of posterior anchorage in these procedures, however, it proves difficult to obtain both sufficient stability and symmetry on the 2 sides owing to the lack of any point of reference. In the lateral crural stairstep technique, the pres-

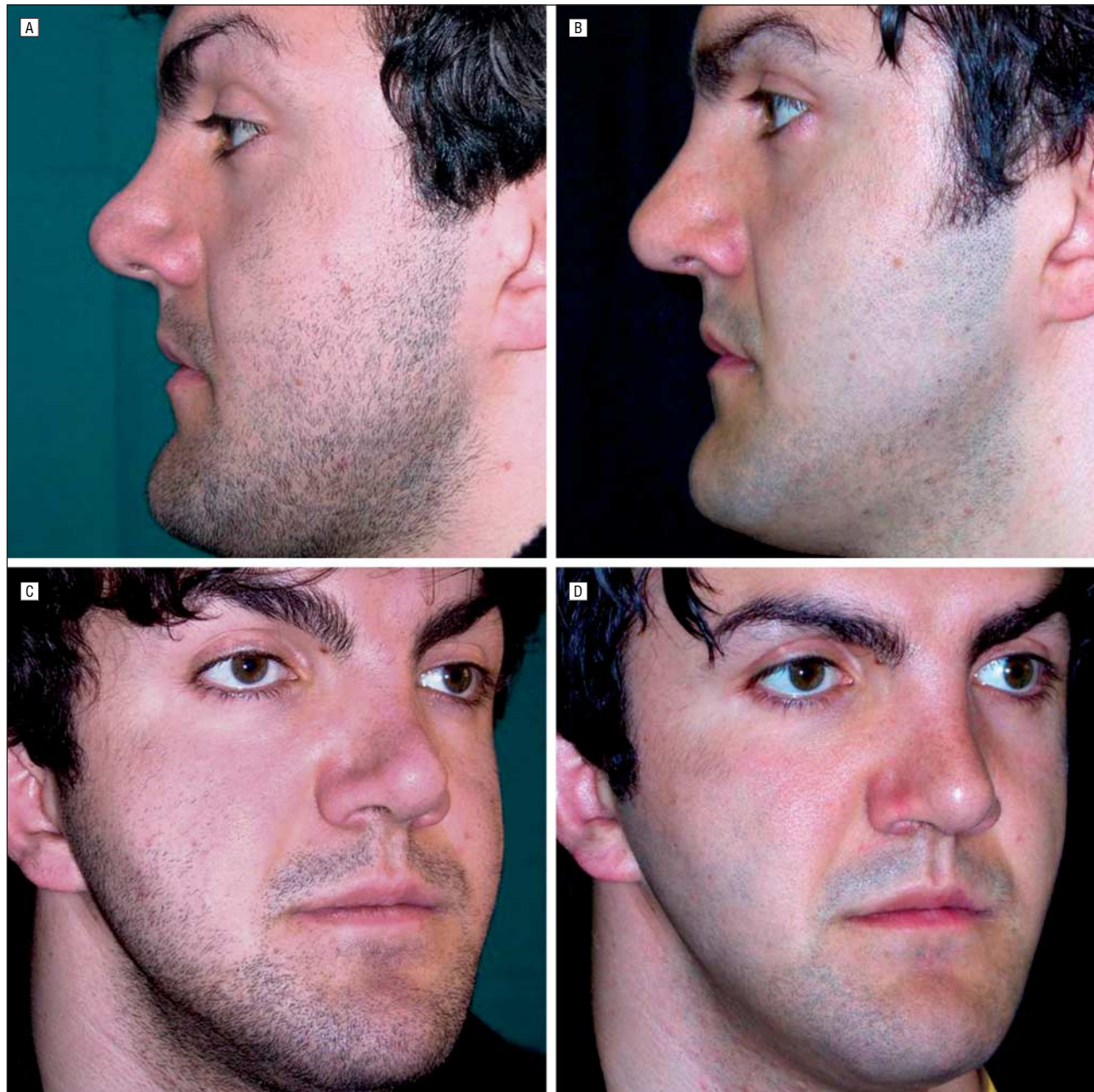

Figure 12. Patient who underwent a previous rhinoplasty with overprojection and overrotation of the tip (correction performed with surgical option in Figure 4D). A and C, Preoperative views; B and D, postoperative views.

ence of the small posterior segment of lateral crus left in its original position, despite its lack of aesthetic importance, makes it possible to change the position of the tip with the certainty of obtaining symmetry on both sides. In point of fact, the stepped shape of the 2 cartilaginous margins brought together gives an immediate visual idea of the measurements with no need for the use of sophisticated instruments.

In conclusion, the technique is capable of modifying 1, 2, or all 3 parameters of the nasal tip (projection, rotation, and position), as required, at the same time and with great precision. Also, the downward rotation of the lateral crura makes more conservative reshaping of the nasal tip possible, with no need for the removal of a sub-

stantial strip from the cephalic portion of the cartilages. Moreover, the overlapping of the 2 cartilage segments for quite a long stretch provides additional support for the alar cartilages and flattens the lateral crura to create an unquestionably better aesthetic effect.

Accepted for Publication: July 22, 2007.

Correspondence: Armando Bocchieri, MD, Viale Umberto Tupini 133, 00144 Rome, Italy (armando.bocchieri@libero.it).

Author Contributions: *Study concept and design:* Bocchieri. *Acquisition of data:* Bocchieri. *Analysis and interpretation of data:* Bocchieri and Raimondi. *Drafting of the manuscript:* Bocchieri. *Critical revision of the manuscript for*

important intellectual content: Bocchieri and Raimondi. *Statistical analysis:* Bocchieri. *Obtained funding:* Bocchieri. *Administrative, technical, and material support:* Bocchieri. *Study supervision:* Bocchieri and Raimondi.
Financial Disclosure: None reported.

REFERENCES

1. Friedman O, Akcam T, Cook T. Reconstructive rhinoplasty: the 3-dimensional nasal tip. *Arch Facial Plast Surg.* 2006;8(3):195-201.
2. Gunter JP, Friedman RM. Lateral crural strut graft: technique and clinical applications in rhinoplasty. *Plast Reconstr Surg.* 1997;99(4):943-952.
3. Toriumi DM. New concepts in nasal tip contouring. *Arch Facial Plast Surg.* 2006;8(3):156-185.
4. Soliemanzadeh P, Kridel RHW. Nasal tip overprojection: algorithm of surgical deprojection techniques and introduction of medial crural overlay. *Arch Facial Plast Surg.* 2005;7(6):374-380.
5. Kridel RW, Scott BA, Foda HM. The tongue-in-groove technique in septorhinoplasty: a 10-year experience. *Arch Facial Plast Surg.* 1999;1(4):246-256.
6. Bocchieri A, Pascali M. Septal crossbar graft for the correction of the crooked nose. *Plast Reconstr Surg.* 2003;111(2):629-638.
7. Bocchieri A. Evolution of the septal crossbar graft technique. *Facial Plast Surg.* 2006;22(4):255-265.
8. Anderson JR. The dynamic of rhinoplasty. In: Bustamant GA, ed. *Proceedings of the Ninth International Congress of Otorhinolaryngology, Mexico City, August 10-14, 1969.* Amsterdam, the Netherlands: Excerpta Medica; 1970:ser 206.
9. Anderson JR. A reasoned approach to nasal base surgery. *Arch Otolaryngol.* 1994;110(6):349-358.
10. Kridel RW, Konior RJ. Controlled nasal tip rotation via the lateral crural overlay technique. *Arch Otolaryngol Head Neck Surg.* 1991;117(4):411-415.